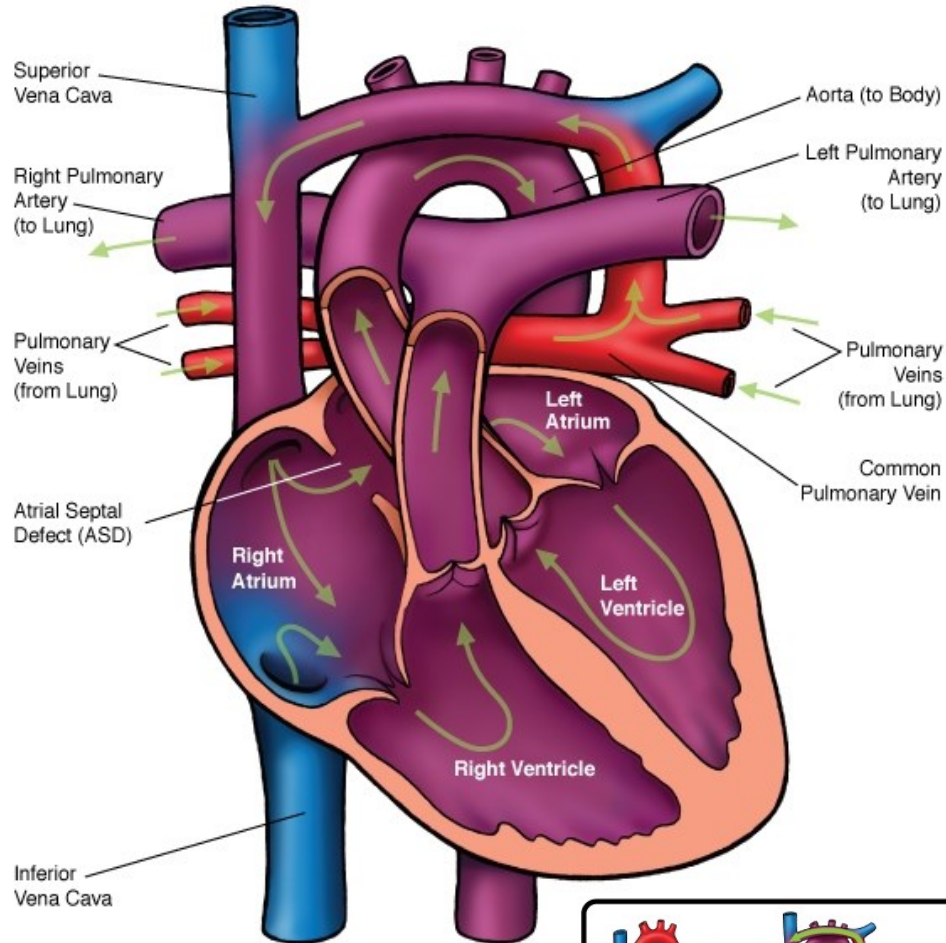
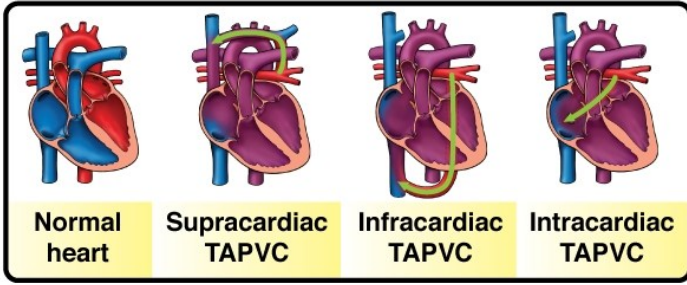




# Total Anomalous Pulmonary Venous Connection (TAPVC) - Supracardiac



NOTES:



Children's Heart Clinic, P.A., 2530 Chicago Avenue S, Ste 500, Minneapolis, MN 55404  
 West Metro: 612-813-8800 \* East Metro: 651-220-8800 \* Toll Free: 1-800-938-0301 \* Fax: 612-813-8825  
 Children's Hospitals and Clinics of MN, 2525 Chicago Avenue S, Minneapolis, MN 55404  
 West Metro: 612-813-6000 \* East Metro: 651-220-6000

---

## Total Anomalous Pulmonary Venous Connection (TAPVC)

In the structurally normal heart, the pulmonary veins drain oxygenated blood from the lungs to the left atrium. In total anomalous pulmonary venous connection (TAPVC), the pulmonary veins do not connect directly to the left atrium. Instead, the pulmonary veins drain above the heart (supracardiac), below the heart (infracardiac) or to the coronary sinus or right atrium (cardiac). The pulmonary veins may also have varying degrees of obstruction due to the length of the venous channels or hepatic sinusoids, resulting in pulmonary hypertension. TAPVC accounts for 1% of all congenital heart defects. Infracardiac type has a higher male to female ratio (4:1).

### Types:

- **Supracardiac:** The pulmonary veins drain to the right superior vena cava (SVC) through the left vertical vein and left innominate vein. This type accounts for 50% of TAPVC.
- **Infracardiac:** The common pulmonary venous sinus drains to the portal vein, ductus venosus, hepatic vein or inferior vena cava (IVC). This type accounts for 20% of TAPVC.
- **Cardiac:** The common pulmonary venous sinus drains into the right atrium through four separate openings or may drain into the coronary sinus. This type accounts for 20% of TAPVC.
- **Mixed:** 10% of patients with TAPVC have a combination of supracardiac, infracardiac or cardiac.

### Physical Exam/Symptoms:

*With* pulmonary venous obstruction, patients may exhibit the following:

- Marked cyanosis (blue coloring) and respiratory distress in the neonatal period.
- Failure to thrive (FTT).
- **Infracardiac type**-worsening symptoms with feeding due to compression of the common pulmonary vein by food in the esophagus.
- Loud, single S2 with gallop rhythm common.
- Usually no murmur.
- Pulmonary crackles and hepatomegaly.

*Without* pulmonary venous obstruction, patients may exhibit the following:

- Slow growth and frequent respiratory infections in infancy.
- Mild cyanosis from birth.
- Congestive heart failure (CHF): tachypnea (fast breathing), dyspnea (difficulty breathing), tachycardia (fast heart rate) and hepatomegaly (enlarged liver) are present.
- Precordial bulge and hyperactive right ventricular impulse is present.
- Widely split and fixed S2. A grade II-III/VI systolic ejection murmur is heard best at the left upper sternal border. Due to increased flow through the tricuspid valve, a mid-diastolic murmur is heard at the left lower sternal border.

---

## Total Anomalous Pulmonary Venous Connection (TAPVC)

### Diagnostics:

- Chest X-ray: *With* pulmonary venous obstruction, the heart appears normal size or slightly enlarged. Pulmonary edema is present, which may be confused with pneumonia. *Without* pulmonary venous obstruction, there are increased pulmonary vascular markings are present with moderate to severe cardiomegaly (enlarged heart) due to right atrial and ventricular dilation.
- EKG: Right ventricular hypertrophy (RVH) is present with or without pulmonary venous obstruction.
- Echocardiogram: Diagnostic. Common features include RVH with a compressed left ventricle (LV), interatrial communication (patent foramen ovale or secundum ASD) with right to left shunting, and increased flow velocity in the pulmonary artery.
- Computed Tomography Angiogram (CTA): Used to confirm location of each pulmonary venous connection.

### Medical Management/Treatment:

- Diuretics before and after surgical repair to manage excess fluid in the lungs.
- Intubation and mechanical ventilation for infants with severe pulmonary edema.
- Prostaglandin E (PGE) is administered preoperatively to keep the ductus arteriosus patent for infants with pulmonary hypertension until the time of surgical repair.
- Surgical repair is necessary for survival. For infants with obstructed pulmonary venous return, surgery should be done soon after diagnosis in the newborn period.
- Lifelong cardiology follow-up every 6-12 months is recommended to evaluate for atrial arrhythmias or obstruction of the pulmonary veins.

### Long-Term Outcomes:

- Rarely, atrial arrhythmias may develop, requiring medications or pacemaker therapy.
- 5-10% of patients develop pulmonary vein obstruction/stenosis 6-12 months after repair.
- No activity restrictions if pulmonary veins remain unobstructed after surgical repair.
- Without surgical repair, 2/3 of infants without pulmonary obstruction will die before 12 months of age. Infants with infracardiac TAPVC rarely survive to 2 months of age without surgery.
- Expected growth and development are normal in the absence of other congenital heart disease or co-morbidities.