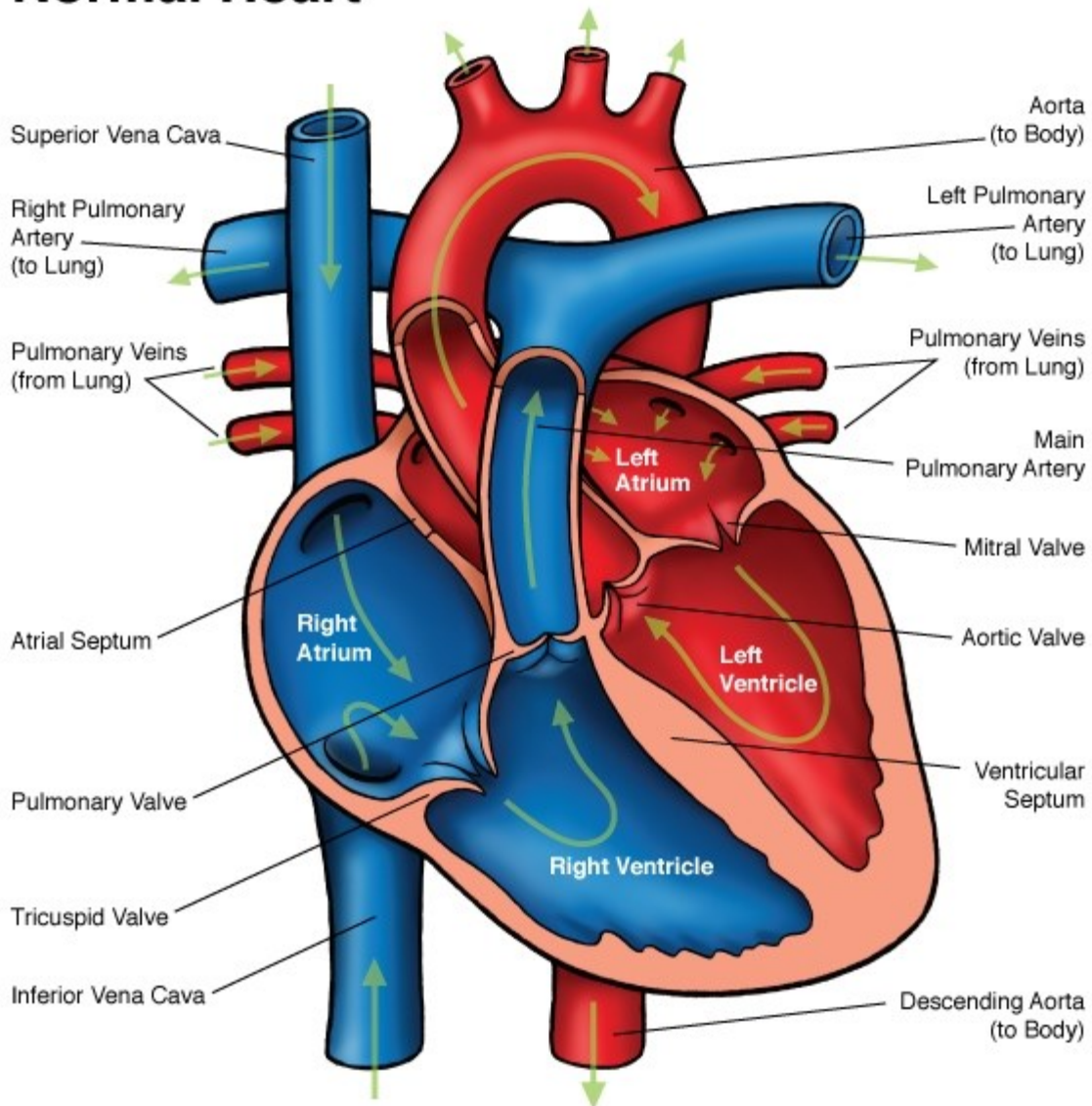




Normal Heart



NOTES:

Children's Heart Clinic, P.A., 2530 Chicago Avenue S, Ste 500, Minneapolis, MN 55404
 West Metro: 612-813-8800 * East Metro: 651-220-8800 * Toll Free: 1-800-938-0301 * Fax: 612-813-8825
 Children's Hospitals and Clinics of MN, 2525 Chicago Avenue S, Minneapolis, MN 55404
 West Metro: 612-813-6000 * East Metro: 651-220-6000

Normal Heart

Blood Flow:

In the normal heart, deoxygenated blood flows from the superior vena cava (SVC) and inferior vena cava (IVC) to the right atrium through the tricuspid valve to the right ventricle. The ventricle contracts and blood is pumped through the pulmonary valve to the pulmonary arteries out to the lungs where the blood is oxygenated. Blood returns from the lungs by the pulmonary veins to the left atrium. It then travels from the left atrium through the mitral valve to the left ventricle. The left ventricle contracts, sending blood through the aortic valve through the aorta and out to the body.

Structures:

- **Myocardium:** The heart is made up of specialized muscle called myocardium that lines the walls of the four chambers (atria and ventricles).
- **Pericardium:** A thin sac that envelops the heart to hold it in place and to keep the heart from over-expanding when blood volume increases.
- **Right atrium:** The right atrium is a low-pressure, thin, smooth-walled chamber. Blood returns from the body to the right atrium via the SVC and IVC. The right atrium houses the sino-atrial node (SA node), the origin of each heart beat.
- **Right ventricle:** A thin, muscle-bound chamber responsible for pumping blood to the lungs via the pulmonary arteries. The right ventricular chamber is crescent-shaped and usually located directly beneath the sternum.
- **Left atrium:** Thin-walled, low pressure chamber. The pulmonary veins return oxygenated blood from the lungs to the left atrium.
- **Left ventricle:** Thick-walled, muscular chamber responsible for pumping oxygenated blood out to the body.
- **Aorta:** Largest blood vessel; responsible for carrying oxygenated blood from the heart out to the body.
- **Septum:** Partition that separates the right and left atria and the right and left ventricle.
- **SVC/IVC:** Large veins that carry deoxygenated blood from the body back to the right atrium.

Heart Sounds:

Heart sounds are described most often by first and second heart sounds. This is commonly known as “lub-dub”. The **first heart sound** (lub) is produced by mitral and tricuspid valve closure. This is best heard at the left lower sternal border and heart apex. The **second heart sound** is produced by aortic and pulmonary valve closure. The second heart sound is single in a newborn and usually *split* (lub-dub-dub) in the child with a normal heart. This is due to closure of the aortic valve occurring just before closure of the pulmonary valve. The degree of splitting of the second heart sound varies with breathing. This heart sound is heart best at the left upper sternal border.

- **Murmur:** There are several types of heart murmurs that occur with a structurally normal heart due to turbulent blood flow. The presence of a murmur alone with no other clinical symptoms usually does *not* indicate a problem with the heart.