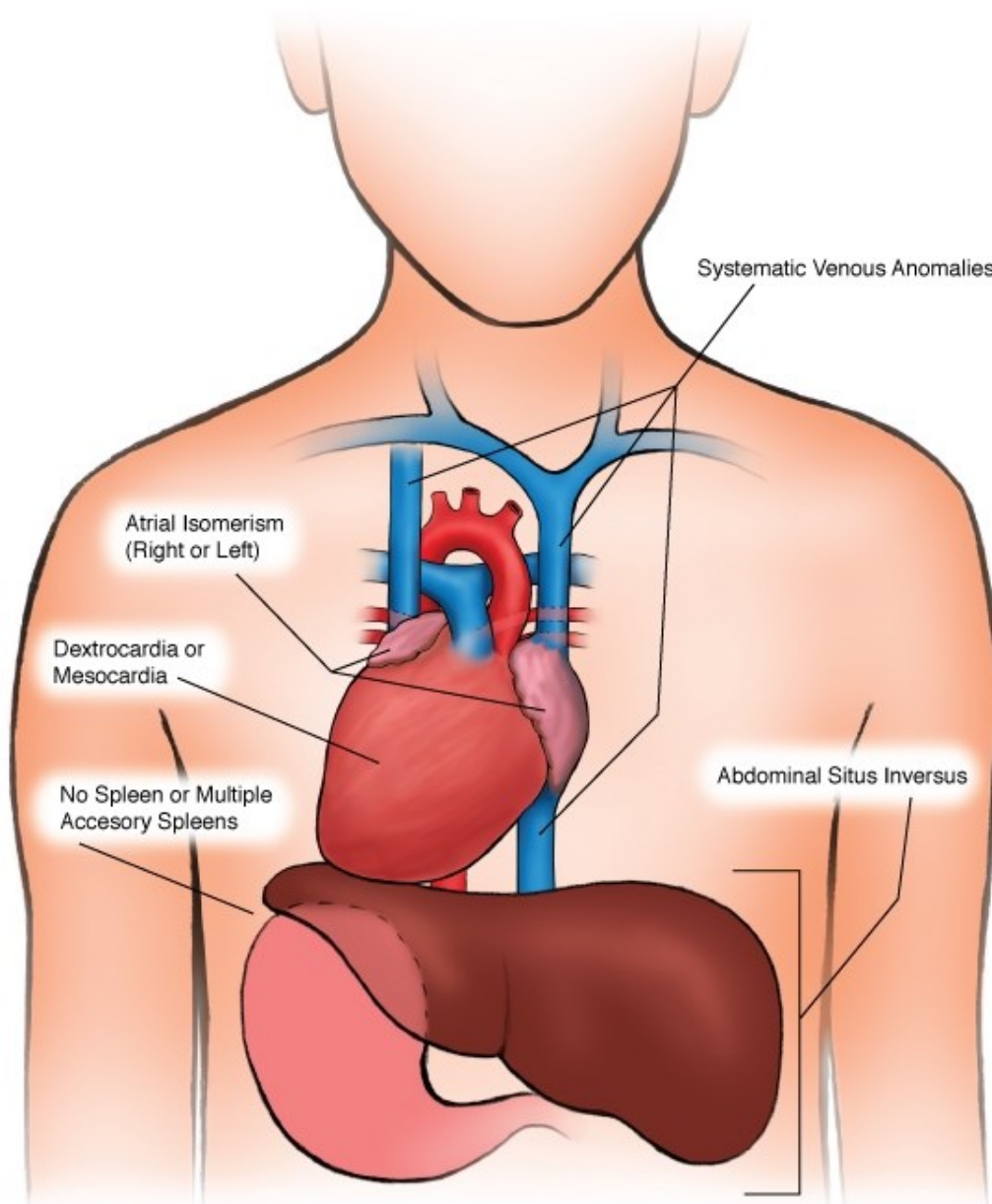




Heterotaxy Syndrome



NOTES:

Children's Heart Clinic, P.A., 2530 Chicago Avenue S, Ste 500, Minneapolis, MN 55404
West Metro: 612-813-8800 * East Metro: 651-220-8800 * Toll Free: 1-800-938-0301 * Fax: 612-813-8825
Children's Hospitals and Clinics of MN, 2525 Chicago Avenue S, Minneapolis, MN 55404
West Metro: 612-813-6000 * East Metro: 651-220-6000

Heterotaxy Syndrome

Heterotaxy (also known as atrial isomerism) refers to the lack of differentiation of right-sided and left-sided organs during fetal development. The exact cause of heterotaxy syndrome is not known. Malformations often occur in multiple organ systems including the heart, liver, lungs, intestine, and spleen. In organs that are normally asymmetrically paired, individuals with heterotaxy have a tendency to have symmetry (for example, two right lungs). Heterotaxy is differentiated as being either right-sided (right atrial isomerism) or left-sided (left atrial isomerism) in general.

Right atrial isomerism is associated with absence of a spleen (asplenia), bilateral right-sidedness of duplicated organs (i.e. two right atria and two right lungs), and cardiovascular abnormalities are often more severe. In the setting of two right atria, there are two sinoatrial nodes. 80% of individuals with right atrial isomerism have transposition of the great arteries (TGA) with pulmonary stenosis or atresia, leading to severe cyanosis shortly after birth. 75% have extracardiac total anomalous pulmonary venous return (TAPVR). Single ventricle physiology is more common than in left atrial isomerism. Right atrial isomerism occurs in 1% of newborns with congenital heart disease and occurs more frequently in males.

Left atrial isomerism is associated with multiple splenic tissues (polysplenia) which may or may not be functional, left-sided organ duplication (i.e. two left atria and two left lungs), and interruption of the inferior vena cava (IVC) with azygous continuation. Two ventricles are usually present. Associated congenital heart disease is often more mild, for example, an isolated VSD. Left atrial isomerism occurs in less than 1% of children with congenital heart disease and occurs more frequently in females.

Heterotaxy syndrome is a constellation of abnormal findings, ranging from very mild and normal circulation to very complex and abnormal circulation. It is hard to discuss heterotaxy syndrome, in a general sense, because it is so variable and each patient is unique.

Physical Exam/Symptoms/Diagnostics:

Right atrial isomerism:

- Severe cyanosis is one of the possible presenting symptoms due to decreased pulmonary blood flow in the setting of pulmonary stenosis or atresia.
- A midline or transverse liver may be palpated.
- Murmur of pulmonary stenosis (PS) or ventricular septal defect (VSD) may be heard along the left sternal border.
- Chest x-ray: The heart may be in the right chest, left chest, or the middle (mesocardia). There is bronchial symmetry (two right lungs) with decreased pulmonary vascular markings if there is restriction to pulmonary blood flow. A midline liver is a classic finding.
- EKG: Variable presentation, but often right ventricular hypertrophy (RVH) and/or left ventricular hypertrophy (LVH) is present. The P axis may alternate between the lower right and left quadrants due to two sinus nodes (two right atria).
- Echocardiogram: Diagnostic.

Left atrial isomerism:

- Infants are usually not cyanotic.
- Signs of CHF may occur early in infancy (increased work of breathing, poor feeding/weight gain, fast heart rate) if a moderate to large VSD is present.
- A murmur may be heard at the left lower sternal border of varying intensity depending on the size of a VSD.
- A midline liver is often present.
- Chest X-ray: Mild-moderate heart enlargement (cardiomegaly) with symmetrical bronchi (two left lungs) and increased pulmonary vascular markings are present if a VSD is present. The liver is midline.
- EKG: Due to the lack of sinus node (normally in the right atrium but these patients have two left atria), the P axis is superior in origin and there is ectopic atrial rhythm.
- Echocardiogram: Diagnostic.

Heterotaxy Syndrome

Medical Management/Treatment:

- For infants with severe cyanosis, prostaglandin E therapy (PGE) should be started as soon as possible to keep the ductus arteriosus patent until further anatomic survey is complete with an echocardiogram.
- Individuals with asplenia require antibiotic prophylaxis against bacterial infection daily until at least 5 years of age (penicillin or amoxicillin). Individuals with polysplenia should also have antibiotic prophylaxis against bacterial infection daily until able to assess whether or not the splenic tissue is functional or not. Immunology consultation is helpful for the patients with Heterotaxy syndrome.
- Immunization against pneumococcus is indicated at 2 years of age for children with asplenia, and may be indicated for those children with polysplenia, but not functional splenic tissue. Other inactivated immunizations are recommended per normal routine. Again, an Immunology consultation is helpful.
- Surgical repair is often necessary for survival if surgical congenital heart disease exists. This is a widely varying subset of patients. Your cardiologist will discuss whether or not surgical options exist for you.
- Pacemaker may be indicated eventually for children with significant bradycardia (slow heart rate).
- Diuretics and afterload reducing medications are used if the underlying anatomic substrate requires.
- Life-long cardiology follow up is necessary for the majority of these patients. If there is no anatomic heart disease, then follow-up can be very infrequent and even as needed in a small minority of patients.

Long-Term Outcomes:

- Without surgical palliation, 95% of patients with asplenia and 60% of patients with polysplenia will not survive past the first year of life.
- Hemodynamically significant cardiac arrhythmias develop in 25% of patients with left atrial isomerism, requiring medications or pacemaker for management.
- Lifespan and development vary widely based on surgical outcomes and the presence or absence of other co-morbidities.