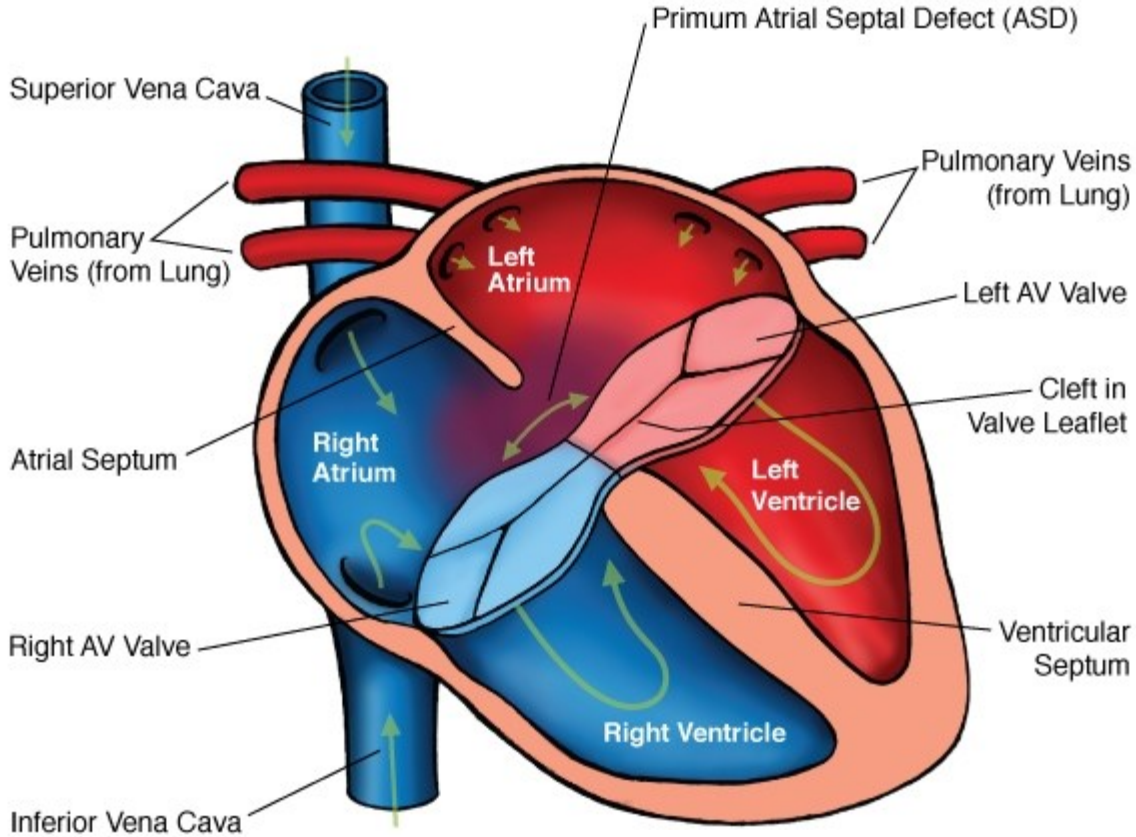
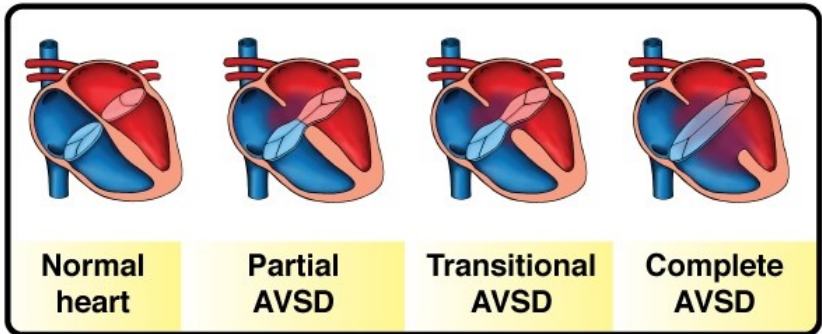




Atrioventricular Septal Defect (AVSD) Partial



NOTES:



Children's Heart Clinic, P.A., 2530 Chicago Avenue S, Ste 500, Minneapolis, MN 55404
 West Metro: 612-813-8800 * East Metro: 651-220-8800 * Toll Free: 1-800-938-0301 * Fax: 612-813-8825
 Children's Hospitals and Clinics of MN, 2525 Chicago Avenue S, Minneapolis, MN 55404
 West Metro: 612-813-6000 * East Metro: 651-220-6000

Atrioventricular Septal Defect (AVSD)

Atrioventricular septal defects (also known as AV canal) result when there are abnormalities of the endocardial cushion tissue. This comprises the atrial and ventricular septum as well as the AV valves (tricuspid and mitral valves). AV canal can be classified as complete, partial, or transitional.

Types:

- **Complete:** A primum atrial septal defect (ASD) and inlet ventricular septal defect (VSD) are present. Clefts in the mitral and tricuspid valve leaflets result in one common, large AV valve connecting the atrial and ventricular chambers. Occurs in 2-3% of all congenital heart defects. Of the children with complete AV canal, 70% have Down Syndrome (Trisomy 21).
 - **Balanced AV canal** refers to midline position of the common AV valve over the two ventricles.
 - **Unbalanced AV canal** occurs when the AV valve orifice is committed primarily to the left or right ventricle. Hypoplasia (underdevelopment) of one ventricle may be present, resulting in the need for single ventricle palliation (see [Modified Blalock-Taussig Shunt](#), [Bidirectional Glenn](#) and [Modified Fontan](#)).
- **Partial:** Also known as “incomplete” AV canal. Primum ASD with separate mitral and tricuspid valve orifices and clefts in the mitral and tricuspid valve leaflets. There is usually a component of mitral (left AV valve) insufficiency. Partial AV canal occurs in 1-2% of all congenital heart defects.
- **Transitional:** Primum ASD, with partial separation of the AV valves. Small or moderate-sized VSDs (often multiple) may be present due to dense chordal attachments.

Physical Exam/Symptoms:

- **Complete AV canal:** Signs of congestive heart failure (fast heart rate, rapid breathing, poor growth/feeding). Holosystolic murmur of varying degree is heard along the left lower sternal border and may transmit to the back.
- **Partial/Transitional:** Often asymptomatic, unless mitral insufficiency is present. In the setting of mitral insufficiency, a murmur may be heard at left lower sternal border and the child may develop symptoms of congestive heart failure.

Diagnostics:

- **EKG:** First degree heart block (prolonged PR interval) and left axis deviation may be present.
- **Chest x-ray:** Cardiomegaly and prominent pulmonary vasculature and main pulmonary artery. The left ventricular outflow tract is elongated and narrowed, often resulting in a “goose-neck” appearance.
- **Echocardiogram:** Diagnostic

Medical Management/Treatment:

- Diuretics and afterload reducing medications are used for anticongestive management.
- Surgical intervention is necessary (see [AVSD repair](#)).
- Life-long cardiology follow up is needed to evaluate AV valve function and competency.

Long-Term Outcomes:

- Life-expectancy varies depending on the severity of valvar disease and/or other comorbidities.
- Bacterial endocarditis prophylaxis is for 6 months after repair and long-term if residual valve leakage or mechanical valve placement.